

12-1987

## An Overview of Magnetic Resonance Imaging of the Appendicular Musculoskeletal System

Sharon C. Siegel

Allan M. Haggar

Jerry W. Froelich

Burton I. Ellis

Follow this and additional works at: <https://scholarlycommons.henryford.com/hfhmedjournal>



Part of the [Life Sciences Commons](#), [Medical Specialties Commons](#), and the [Public Health Commons](#)

---

### Recommended Citation

Siegel, Sharon C.; Haggar, Allan M.; Froelich, Jerry W.; and Ellis, Burton I. (1987) "An Overview of Magnetic Resonance Imaging of the Appendicular Musculoskeletal System," *Henry Ford Hospital Medical Journal* : Vol. 35 : No. 4 , 234-244.

Available at: <https://scholarlycommons.henryford.com/hfhmedjournal/vol35/iss4/15>

This Article is brought to you for free and open access by Henry Ford Health System Scholarly Commons. It has been accepted for inclusion in Henry Ford Hospital Medical Journal by an authorized editor of Henry Ford Health System Scholarly Commons.

## An Overview of Magnetic Resonance Imaging of the Appendicular Musculoskeletal System

Sharon C. Siegel, MD,\* Allan M. Hagggar, MD,† Jerry W. Froelich, MD,‡ and Burton I. Ellis, MD§

Magnetic resonance imaging (MRI) has rapidly become a powerful diagnostic tool in evaluating disorders of the musculoskeletal system. MRI does not utilize x-radiation to create an image. Multiplanar imaging is possible in a completely noninvasive manner without moving the patient. Contrast differences between obvious normal and abnormal body tissues are detectable by MRI and provide a sensitive means of detecting normal from pathological tissue. Because of the absence of signal from normally patent blood vessels, main vascular structures are visible without the need for intravenous contrast agents.

We provide an overview of the major uses to date of MRI in the appendicular musculoskeletal system, including noninvasive detection of injuries of the knee, tumor staging, and early evaluation of avascular necrosis. In addition, we briefly discuss the use of MRI in other bone and soft tissue disorders, such as marrow infiltrative diseases and osteomyelitis.

### Basic Physics

Nowhere in diagnostic imaging is an understanding of the physics so important to the interpretation of the final image. Therefore, a basic comprehension of the physical principles of MRI is critical in interpreting the final image. As noted, MRI does not utilize x-rays in producing a final image. In contradistinction to x-ray computed tomography, where differences in densities of tissues are determined by relative attenuation coefficients secondary to electron density, MRI relies on the magnetic properties of tissues when placed in a magnetic field and subjected to radio frequency pulses.

Nuclei possessing an odd number of nucleons (protons and neutrons) demonstrate a property termed spin. Nuclei with spin have a magnetic moment, and thus generate a small magnetic field. In essence, these nuclei are like small bar magnets possessing definite magnitude and direction of their lines of force, and therefore can be thought of as vector quantities. When placed within an external magnetic field, these vectors or spins orient themselves both parallel and antiparallel to the main magnetic field. Eventually, the number of nuclei oriented parallel and antiparallel to the applied field is similar, resulting in a net magnetic vector of zero. A small number of protons in excess

to the above parallel and antiparallel spins orient themselves parallel to the field, and therefore a net magnetization results. This condition is necessary for the nuclear magnetic resonance experiment to be performed.

To obtain information from a sample (patient), it is necessary to change or deflect orientation of protons within the sample momentarily. This is performed by the application of radio-frequency pulses in the presence of the magnetic field. Therefore, protons are deflected 90 degrees from their original orientation parallel to the main magnetic field. By rotating these into a plane 90 degrees to their original orientation, a signal can be detected as the protons release energy while returning to their equilibrium state. The time required for a proton to return to its original longitudinal orientation after excitation is described by the time constant T1. T2 describes the time constant characterized by loss of magnetization in the transverse plane. By altering the timing of the radiofrequency pulses, it is possible to produce images which are T1 or T2 weighted. This results in differential contrast which is of diagnostic value.

The production of an image is dependent upon computer analysis of magnetic resonance signals which have been spatially encoded. That is, through the use of magnetic field gradients, it is possible to determine the spatial location of signals coming from a sample (patient) (1).

### MRI of Normal Bone

On MRI, normal bones are characterized by high signal intensity of the central medullary canal with rather dark borders characterizing the cortex. Because of the absence of mobile protons, cortical bone demonstrates no signal. The high-intensity signal of the central portion of bone is a result of the presence of normal

Submitted for publication: June 5, 1987.

Accepted for publication: July 17, 1987.

\*Formerly Department of Diagnostic Radiology and Medical Imaging, Henry Ford Hospital. Currently Department of Radiology, Sinai Hospital of Detroit.

†Department of Diagnostic Radiology and Medical Imaging, Henry Ford Hospital.

‡Division of Magnetic Resonance Imaging, Henry Ford Hospital.

§Division of Skeletal Radiology, Henry Ford Hospital.

Address correspondence to Dr. Hagggar, Department of Diagnostic Radiology and Medical Imaging, Henry Ford Hospital, 2799 W Grand Blvd, Detroit, MI 48202.

marrow f  
the prese  
are an exc  
normal si  
process a  
ture is of  
subcutan  
conventi  
void due t  
normalitie  
be easily c  
dle can be  
material (

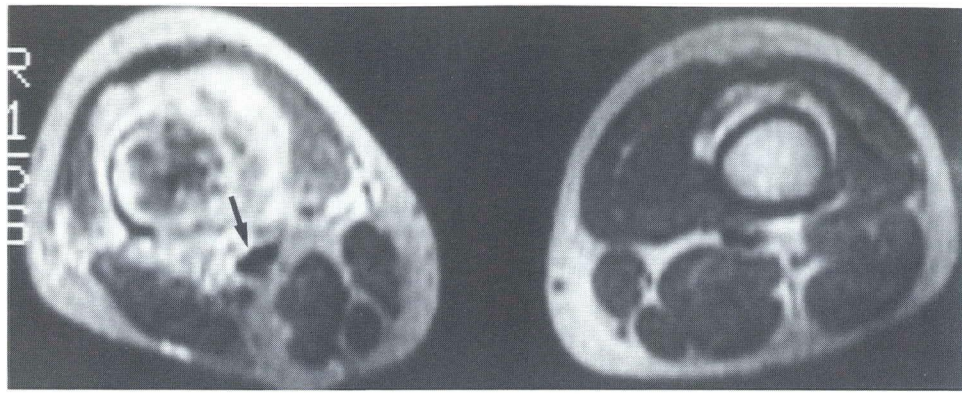
AV:

Avascu  
encounter  
because a  
even rever  
tive moda  
is currentl  
early AVI

AVN is  
bone marr  
to the ferr  
trauma, sn  
row infiltr  
congenita  
children. I

Sustain  
lular elem  
bone cells  
high signa  
death, the  
creased sig

early AVN  
Four ba  
3): 1) hom



*Fig 1—Teenager with osteogenic sarcoma. The right thigh shows extensive tumoral destruction of distal femur. Central portion of the bone demonstrates high and low signal areas due to tumor bone and nonossified tumor. Arrow indicates neurovascular bundle. High signal areas beyond bone are due to tumor and/or edema. Note muscular atrophy.*

marrow fat. Both T1- and T2-weighted images are sensitive to the presence of marrow disturbances, but T1-weighted images are an excellent way of screening patients for the presence of abnormal signal intensity, which may be indicative of a pathologic process affecting normal marrow fat. Surrounding musculature is of lesser signal intensity when compared to marrow and subcutaneous fat. Blood vessels are easily demonstrated with conventional pulse sequences and appear as an area of signal void due to flowing blood which emits no signal. Therefore, abnormalities of bones such as tumors or soft tissue sarcomas can be easily outlined, and the relationship to the neurovascular bundle can be ascertained without the need for intravenous contrast material (Fig 1).

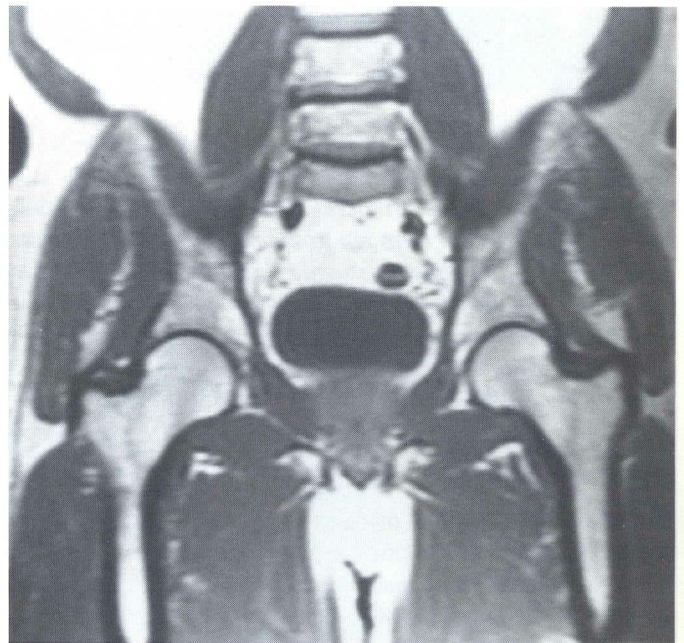### **Avascular Necrosis of the Femoral Head**

Avascular necrosis (AVN) of the femoral head is a commonly encountered clinical entity. Early detection of AVN is essential because appropriate surgical intervention may stop or possibly even reverse progression of the disorder (2,3). MRI is an effective modality in imaging the changes associated with AVN and is currently considered the most sensitive method of detecting early AVN of the femoral head (4).

AVN is felt to be a complication of ischemia of the bone and bone marrow. Causes which predispose to AVN include trauma to the femoral head, steroid usage, Cushing's disease, barotrauma, small vessel disease, alcoholism, pancreatitis, and marrow infiltrative disorders. Slipped capital femoral epiphysis and congenital hip dislocation are predisposing causes of AVN in children. Idiopathic AVN occurs in adults as well as children.

Sustained ischemia to bone results earliest in death of the cellular element within the bone, including hematopoietic cells, bone cells, and fat cells (5). Living fat cells give a characteristic high signal on T1- and T2-weighted images (Fig 2). It is fat cell death, therefore, which presumably is responsible for the decreased signal intensity seen in the femoral head in patients with early AVN.

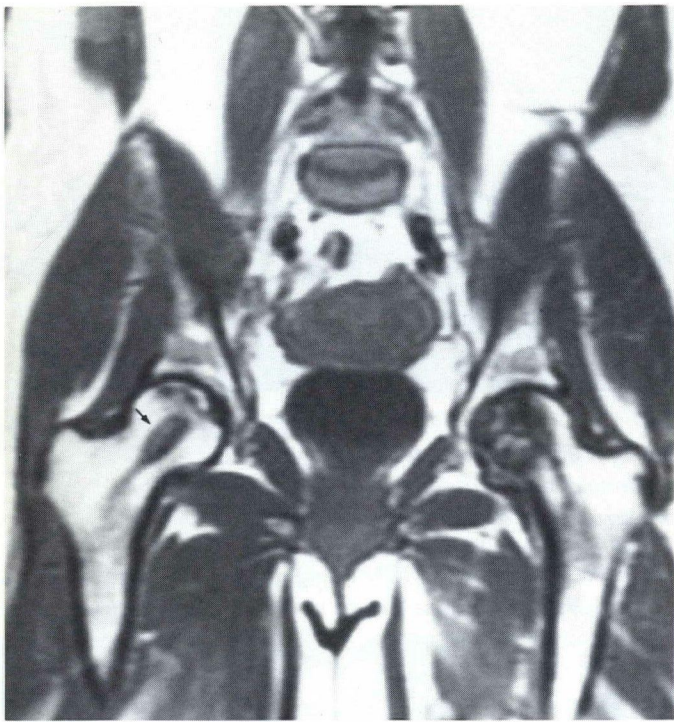
Four basic MRI patterns in AVN have been described (6) (Fig 3): 1) homogeneous, well-defined region of low signal intensity



*Fig 2—Coronal T1-weighted spin echo image (SE800/25 msec) demonstrates normal signal arising from both femoral heads. Note excellent display of surrounding musculoskeletal anatomy. No evidence of AVN.*

in the superior, subarticular aspect of the femoral head; 2) larger, irregular areas of low signal intensity, often involving the entire femoral head (changes may extend into the femoral neck); 3) band of decreased signal intensity extending across the low femoral head or high femoral neck; and 4) ring of decreased signal intensity with a central area of normal signal intensity. Any of these patterns can be seen in early or late AVN, without a consistent correlation between the pattern and the stage of AVN (6).

MRI is currently considered the most sensitive method of detecting early AVN, surpassing plain film radiography-tomography, computed tomography, and nuclear scintigraphy (4).



*Fig 3—Coronal image. Bilateral AVN. T1-weighted spin echo image shows defect in right hip from previous core decompression (arrow). Right hip shows subtle changes of AVN. Extensive signal loss is in the left femoral head with a geographic-appearing lesion involving much of the central portion of the femoral head and portions of the weight-bearing surface. MR findings are typical of AVN.*

However, MRI findings of decreased signal intensity in the femoral head are not specific for AVN; most processes that can replace or infiltrate fatty marrow may cause decreased signal intensity (7). Therefore, the MRI diagnosis of AVN must be correlated with the clinical impression. The pattern of abnormality, particularly in the femoral head, together with the clinical history usually leads to a correct diagnosis.

AVN involving sites other than the femoral head have been studied by MRI, including the carpal bones (8), knees (9), and talus as well as other sites (10) (Fig 4). Work in these other areas, though still in an early stage, holds promise that MRI will provide additional information to that which is currently obtained from other imaging modalities.

### **Injuries of the Cartilages and Ligaments of the Knee**

MRI provides a noninvasive means of detecting injuries of the cartilages and ligaments of the knee. Prior to MRI, invasive methods such as arthrography and arthroscopy were relied upon to detect abnormalities of new structures.

Images obtained in the sagittal plane are most helpful for evaluating the menisci (Fig 5) and cruciate ligaments (Fig 6). Coronal images are usually obtained as well, providing another view of the menisci; the collateral ligaments are also well seen in this plane. Occasionally, oblique images are helpful in evaluating the anterior cruciate ligament. T1-weighted images are usually sufficient for evaluating the ligaments and cartilages of the knee. T2-weighted images may be of value in detecting a joint effusion, but are not routinely performed in our institution. All images are obtained using a surface coil for increased spatial resolution.

Regardless of the pulse sequence used, normal tendons, ligaments, and menisci have low signal intensity, secondary to a lack of mobile protons in these structures. Cortical bone is also of low signal intensity, again secondary to a lack of mobile protons, whereas high signal intensity in the medullary cavity of bone occurs due to living marrow fat cells (Fig 2). Articular (hyaline) cartilage is of intermediate signal intensity on T1-weighted images and can usually be distinguished from the dark cortical bone and dark fibrocartilaginous menisci. Work with high-speed imaging of the knee using new magnetic resonance techniques refined at Henry Ford Hospital has allowed improved visualization of articular cartilage. A controlled study assessing the integrity of articular cartilage is needed (Fig 7).

Possible meniscal tears are the most common injury presently evaluated by MRI. Tears appear as an area of abnormal increased signal intensity within the meniscus. This is most likely secondary to synovial fluid within the cleft of the tear (11). Discoid menisci are also demonstrated noninvasively, which is an important consideration in the pediatric population (Fig 8).

Meniscal tears are divided into four categories according to a grading system modified from work by Lotysch et al (12):

**Grade 1:** Punctate, focal area of increased signal intensity within the meniscus. This type of "tear" is not visible arthroscopically. In asymptomatic patients, this finding may represent an area of myxoid degeneration rather than an actual tear. Its real clinical significance is questionable [Fig 9(A)].

**Grade 2:** Linear area of increased signal intensity, not extending to the meniscal surface, but within the substance of the meniscus. Both magnetic resonance grade 1 and grade 2 tears, being intrameniscal abnormalities, are invisible arthroscopically. A small number of grade 2 tears as seen with MRI may, at arthroscopy, represent grade 3 abnormalities [Fig 9(B)].

**Grade 3:** Linear area of increased signal intensity, extending to the meniscal surface. This tear is arthroscopically visible and is the "garden variety" full-thickness tear usually seen on arthrography [Fig 9(C)].

**Grade 4:** Complete disruption of the meniscus, with linear and nonlinear areas of increased signal intensity throughout the meniscus and/or meniscocapsular separation [Fig 9(D)].

ul for eval-  
g 6). Coro-  
other view  
seen in this  
evaluating  
are usually  
of the knee.  
joint effu-  
ution. All  
sed spatial

ons, liga-  
ndary to a  
one is also  
obile pro-  
y cavity of  
Articular  
ity on T1-  
m the dark  
Work with  
resonance  
d improved  
y assessing

y presently  
normal in-  
most likely  
r (11). Dis-  
which is an  
Fig 8).  
ording to a  
(12):

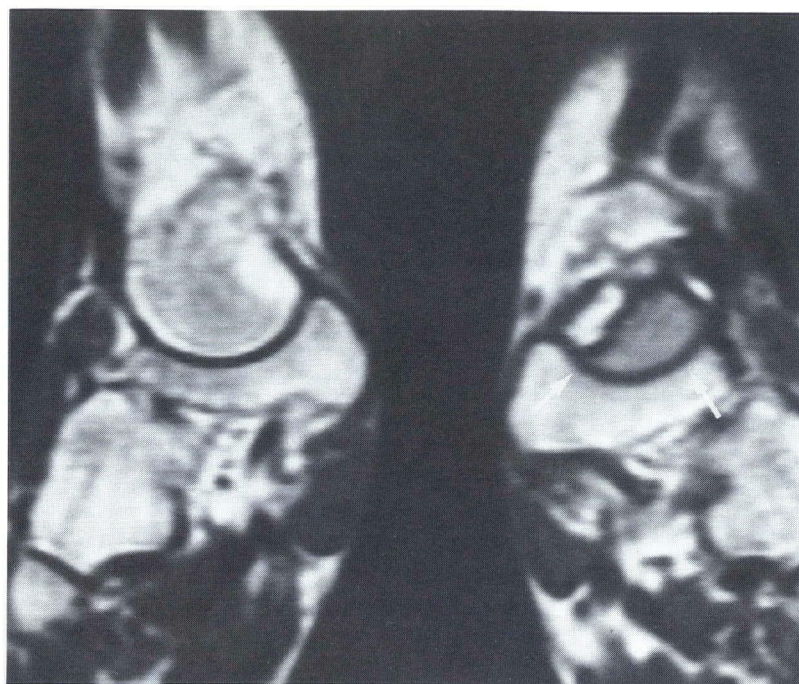
l intensity  
ble arthro-  
y represent  
ear. Its real

not extend-  
of the me-  
de 2 tears,  
roscopical-  
may, at ar-  
].

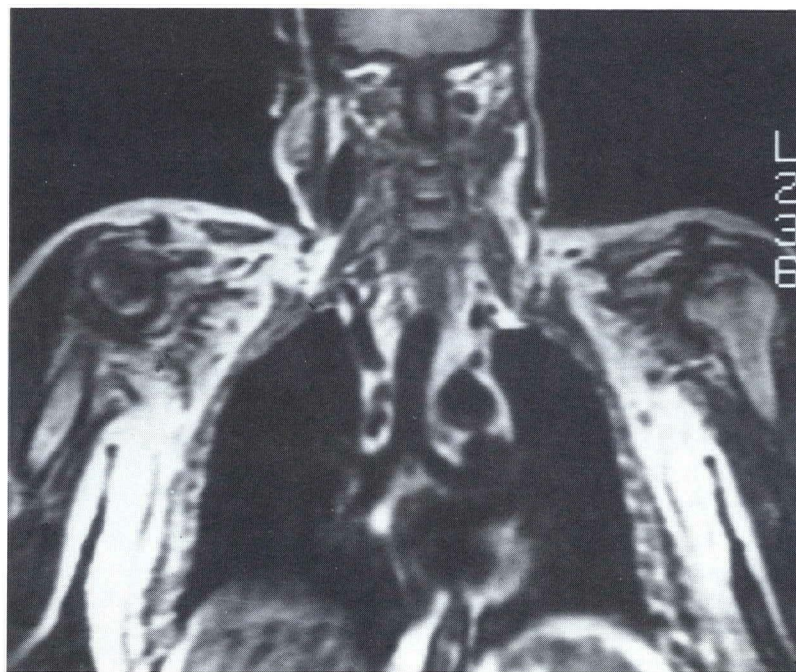extending  
visible and  
ly seen on

with linear  
ughout the  
D)].

m—Siegel et al



*Fig 4(A)—Coronal MR image through the talonavicular joint of the left foot (arrows). Notice diminished signal intensity with evidence of fracture line through the distal talus. Diminished signal intensity from the talus suggests abnormal marrow process.*



*Fig 4(B)—Steroid-induced AVN. Coronal spin echo T1-weighted image through the chest and shoulders demonstrates marked signal loss compatible with AVN of the right humeral head. Note linear band of diminished signal intensity within the left humeral head. Both findings indicate AVN with more severe involvement on the right.*

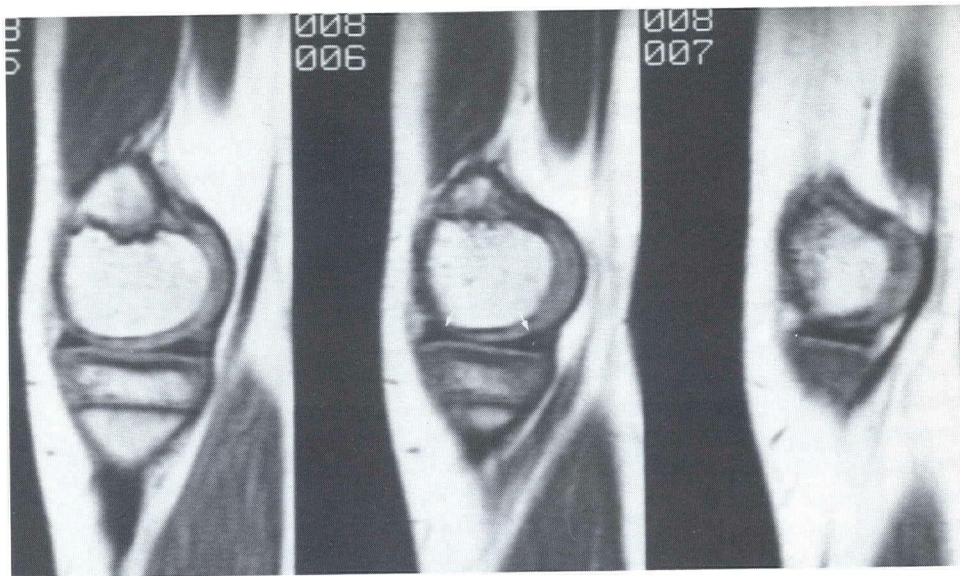


Fig 5—Serial sagittal images through the medial meniscus. Normal medial meniscus demonstrating relative signal void due to presence of fibrocartilage (arrows).

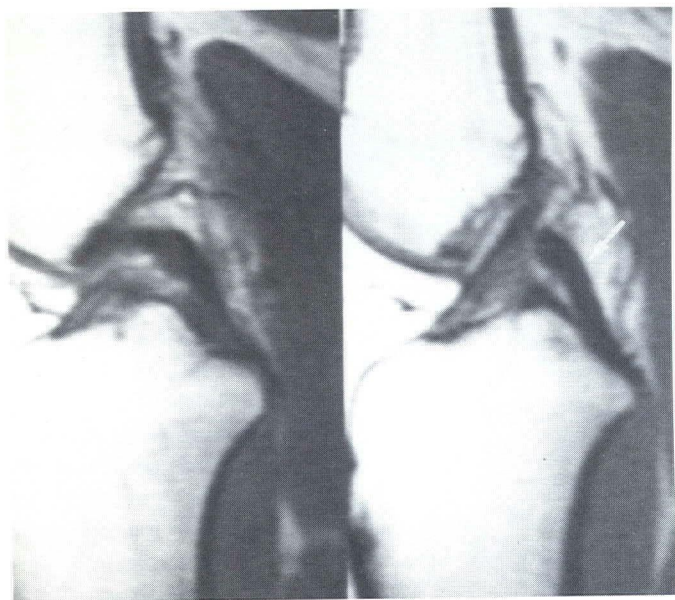


Fig 6—Sagittal image of the knee. Notice excellent display of the cruciate ligaments. The posterior cruciate ligament is easily seen (arrow). Anterior cruciate also well displayed in this image.

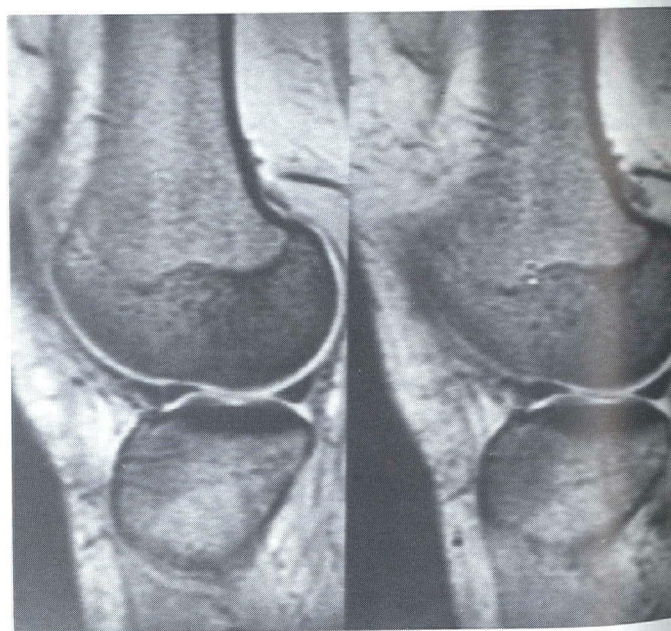
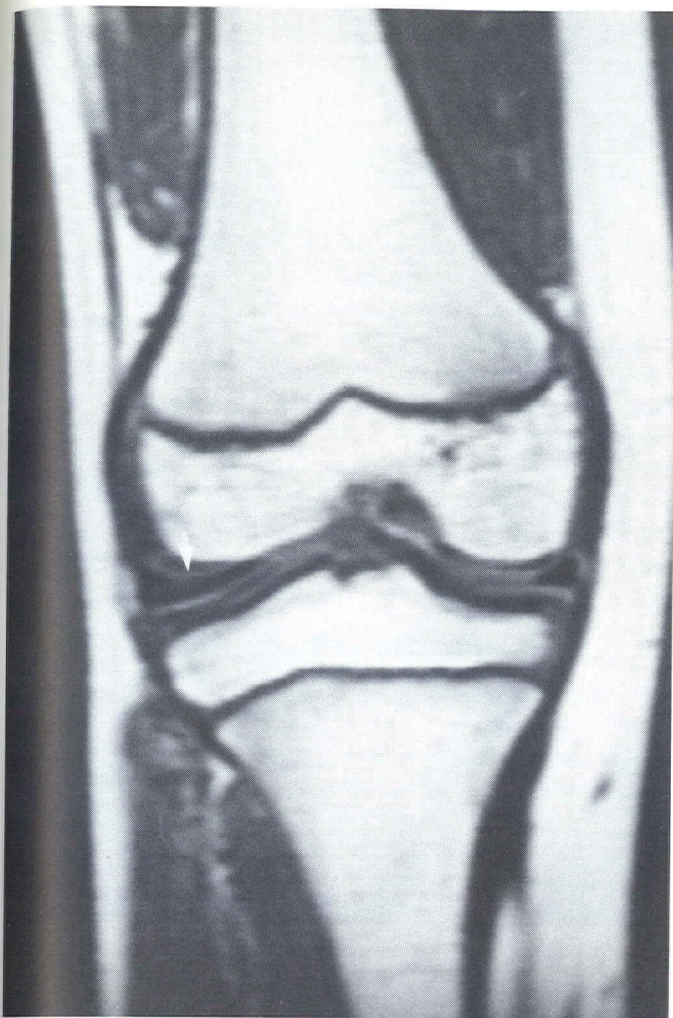


Fig 7—High-speed three-dimensional acquisition MR image of the knee (gradient recalled echo in the steady state) noticed persistent low signal of normal-appearing meniscus. Articular hyaline cartilage is of high signal intensity with this pulse sequence facilitating its visualization.

Fig 8—F...  
partments...  
pression v...  
obvious a...  
meniscus...  
figuration

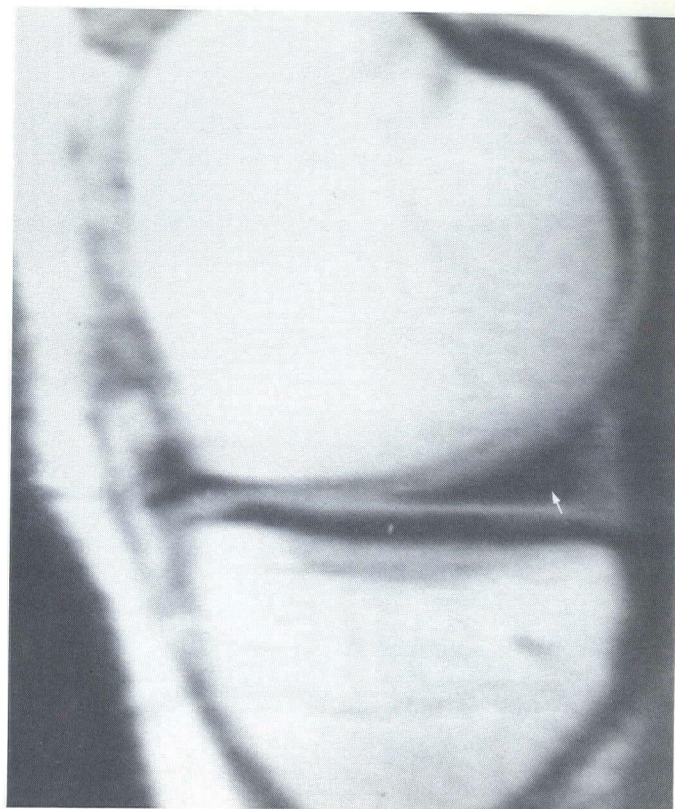
In a rec...  
found to b...  
at arthrosc...  
though lar...  
suspected...  
subsequen...  
tears dete...  
While this...  
also reflect...  
meniscal t...  
face. Inde...  
grade 2 te...  
represent f...  
The mec...  
most regio



*Fig 8—Four-year-old girl with persistent bilateral, lateral compartmental widening on conventional radiographs. Clinical impression was that of discoid menisci. Coronal MR images show obvious asymmetry of the lateral meniscus relative to the medial meniscus. The former is thicker and demonstrates typical configuration of a discoid meniscus seen on arthrography (arrow).*

In a recent study, the predictive value of a negative MRI was found to be 100%; that is, no meniscal tears were demonstrated at arthroscopy in cases that MRI described as negative (13). Although larger studies are needed, a negative MRI in a patient suspected of having a meniscal tear may obviate the need for subsequent arthroscopy. In the same study, 80% of the meniscal tears detected by MRI were found by subsequent arthroscopy. While this may reflect false-positive MRI examinations, it may also reflect false-negative arthroscopic examinations, where the meniscal tear did not extend to an arthroscopically visible surface. Indeed, upon probing at arthroscopy, magnetic resonance grade 2 tears may extend to the articular surface and actually represent full-thickness tears.

The medial (tibial) collateral ligament is attached to the outermost region of the medial meniscus and tends to be injured in

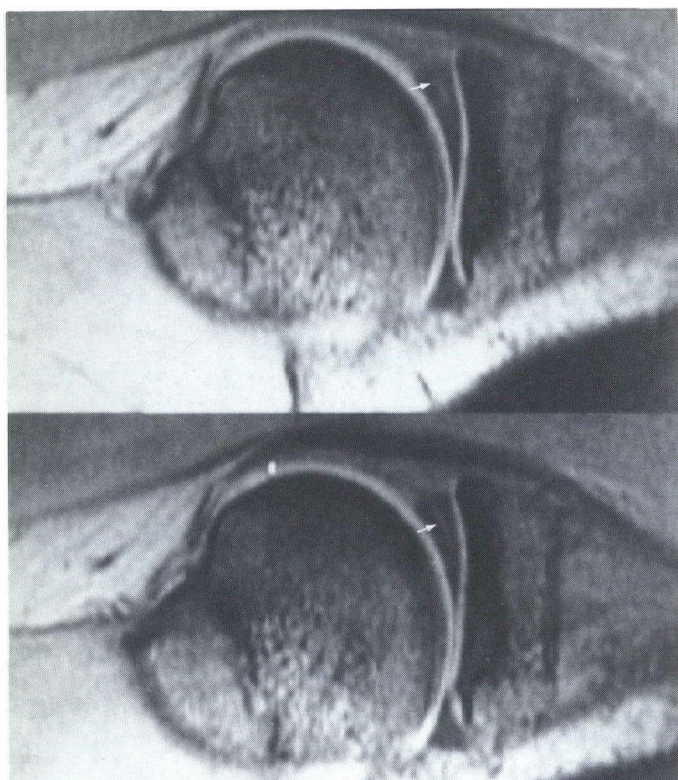


*Fig 9(A)—Punctate high signal focus in the posterior horn of the medial meniscus (arrow). An extremely common finding, this is probably of no clinical significance.*

association with injury to the medial meniscus. The lateral (fibular) collateral ligament does not have a meniscal attachment. Tears of the collateral ligaments (best seen in the coronal plane) demonstrate an area of increased signal intensity within the normally low signal ligament (14). There is associated edematous subcutaneous tissue which emits a high signal intensity on T2-weighted images (15). Avulsion of the collateral ligaments may be imaged directly on coronal images.

Tears of the anterior or posterior cruciate ligaments are seen as an area of increased signal intensity within the normally low signal ligament (Fig 10). This is probably secondary to synovial fluid located between the disrupted ligaments (14). The posterior cruciate ligament is thicker than the anterior cruciate ligament and is well-visualized in the sagittal plane, usually on a single scan. The anterior cruciate ligament tends to be more fan-like in appearance (13) and is often not seen in its entirety on a single sagittal section; therefore, interpretation of injury to the anterior cruciate ligament may be difficult (14). Occasionally, oblique views or sagittal scans with the knee held in flexion may be helpful. In our institution, however, direct angled oblique sagittal views are obtained in order to visualize the anterior cruciate ligament in its entirety. Avulsion of the cruciate ligaments from their attachments may be detected as well as tears, although non-displaced avulsions may be difficult to visualize (15).

MR image  
ate) noticed  
cus. Artic-  
h this pulse



*Fig 9(B)—High-speed three-dimensional technique showing linear high signal focus in the posterior horn of medial meniscus compatible with a grade 2 tear (arrows). This lesion is of doubtful functional significance, but can be observed in patients with pain.*

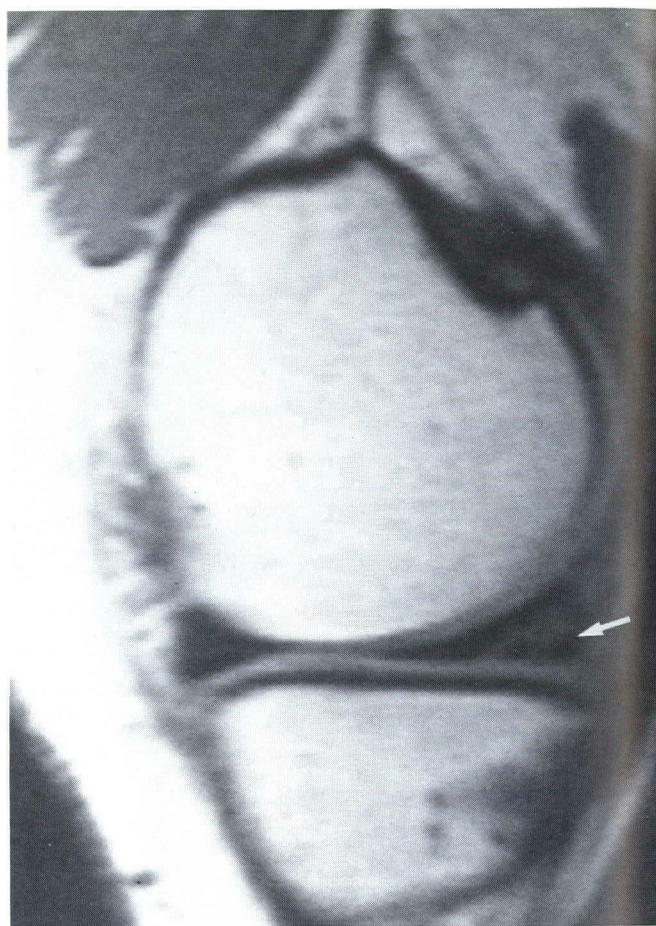The patellar tendon is demonstrated as a contiguous, low-intensity structure on sagittal images. Although large series have not yet been performed, tears and avulsion of the patellar tendon have been described (11,13).

When distended with fluid, the medial and lateral bursae of the knee (pes anserina and lateral fibular bursae) may be visible as clinical causes of knee discomfort (Fig 11).

### Bone and Soft Tissue Neoplasms

Several early studies have been performed to assess the ability of MRI to diagnose and stage neoplasms of bone and soft tissue. These studies indicate that MRI is a useful adjunct in staging the extent of malignant soft tissue or bone neoplasms, but it is not the modality of choice in establishing diagnosis of benignancy versus malignancy or, in most cases, a specific tumor type (16,17). Recent work establishes MRI as the modality of choice in determining the extent of either primary soft tissue neoplasms or the soft tissue extent of primary bone tumors (18).

It was originally hoped that malignant bone and soft tissue neoplasms would have specific MRI signal characteristics distinguishing them from benign lesions. However, in most cases, both benign and malignant lesions demonstrate decreased signal



*Fig 9(C)—Grade 3 tear posterior horn medial meniscus (arrow). There is disruption of the posterior horn with extension of tear to the articular surface of the tibial plateau. There is a high correlation between MR findings and findings at arthroscopy when this abnormality is seen.*

intensity on T1-weighted images and increased signal intensity on T2-weighted images. The exceptions are lipomas, which show characteristic very bright signal intensity on both T1- and T2-weighted images, and bone-producing tumors or tumors composed almost exclusively of fibrous tissue, which demonstrate low signal intensity on T1- and T2-weighted images (19). As with computed tomography, however, differentiation of lipoma from liposarcoma may be difficult.

Patterns of tumor matrix mineralization, if present, are important in predicting the histologic type of neoplasm. This is best demonstrated on plain film radiographs-tomograms or by computed tomography. On MRI, calcifications appear as areas devoid of signal; these may be quite subtle (16,19). This lack of ability to detect matrix mineralization severely limits the utility of MRI in characterizing a neoplasm for purposes of establishing a histologic diagnosis. Therefore, plain films remain the imaging cornerstone for characterizing primary lesions of bone.

While MRI cannot establish a histologic diagnosis, some criteria for suggesting benignancy or malignancy by MRI have

been des-  
film diag-  
fined inh-  
malignan-  
tumor su-  
ings are  
benign o-

The m-  
mented  
herent tis-  
contrast  
enabling  
the medu-  
(16,17) (C  
coronal,  
the long  
niques ut-  
detect th-  
imaging  
planning  
an algori-  
the evalu-  
(Fig 14).

The ro-  
plasm an-  
well stud-  
not have



been described (17,19). These are similar to criteria used in plain film diagnosis. Evidence of cortical destruction and poorly defined inhomogeneous signal intensity within the tumor suggests malignancy. A well-defined low-intensity rim surrounding the tumor suggests a benign process. However, none of these findings are specific enough to conclusively characterize a lesion as benign or malignant based solely on MRI.

The major role of MRI is in staging the local extent of a documented malignancy of soft tissue or bone. MRI has superior inherent tissue contrast resolution (without the use of intravenous contrast media) as compared with computed tomography, thus enabling accurate detection of the extent of the neoplasm within the medullary cavity of the bone and/or within the soft tissues (16,17) (Figs 12 and 13). In addition, MRI can directly image in coronal, sagittal, and oblique planes; this allows visualization of the long axis of the tumor, without image reformatting techniques utilized in computed tomography. The ability of MRI to detect the extent of malignancy more accurately than other imaging modalities should be of great value in preoperative planning of limb-salvage surgery (20). At Henry Ford Hospital, an algorithm has been designed for the current role of imaging in the evaluation of primary neoplasms of soft tissues and bone (Fig 14).

The role of MRI in assessing postoperative recurrence of neoplasm and/or response to radiation/chemotherapy has not been well studied, but is potentially promising. Currently, MRI does not have a role in evaluating the whole body for distant skeletal

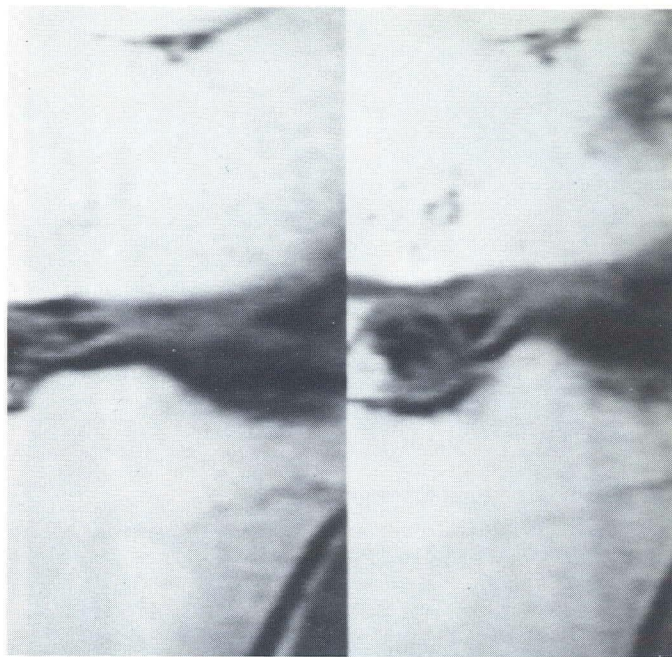


Fig 9(D)—Grade 4 tear in patient with lateral joint line pain. There is marked fragmentation of the anterior horn of the lateral meniscus.

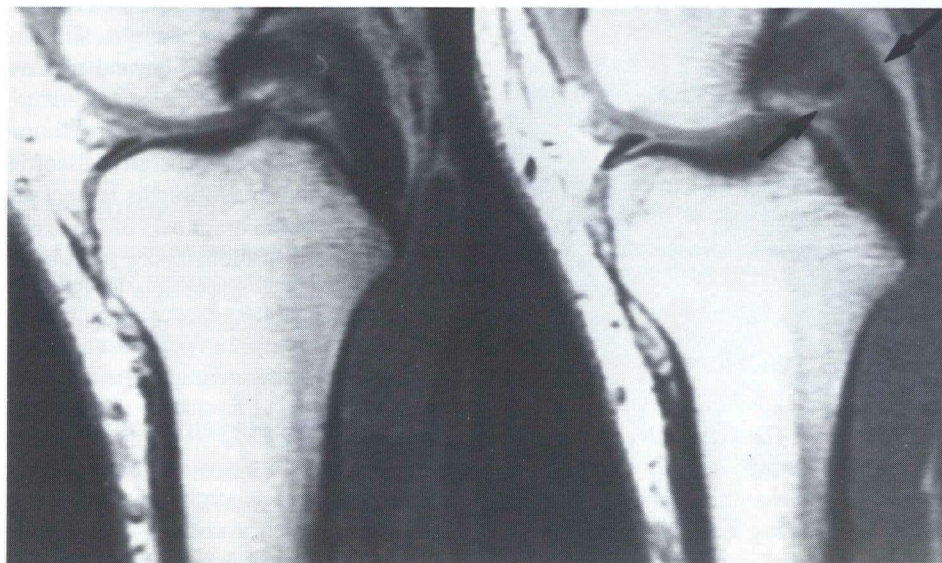
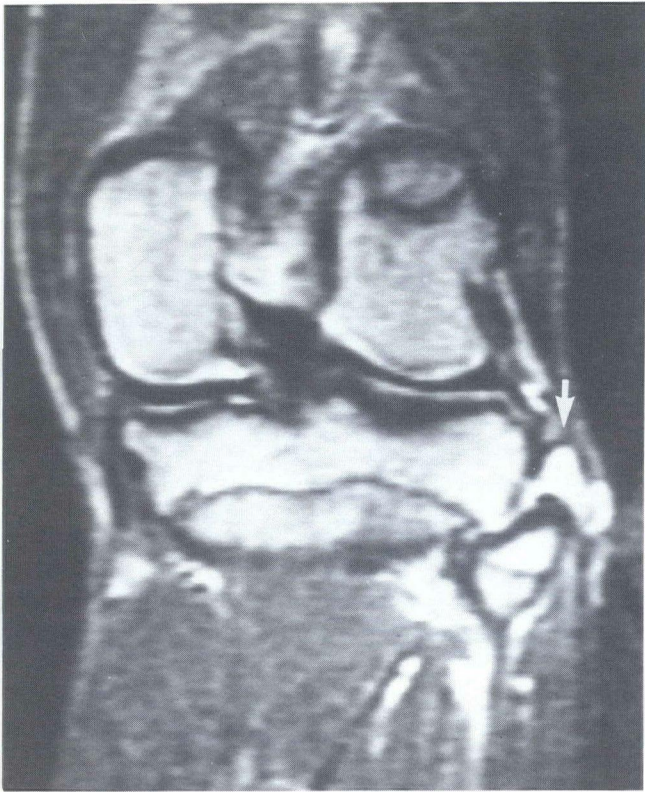


Fig 10—Athlete with posterior cruciate ligament tear. In distinction to Fig 6, there is “fuzziness” and discontinuity of the posterior cruciate ligament due to virtually full-thickness disruption (arrows).

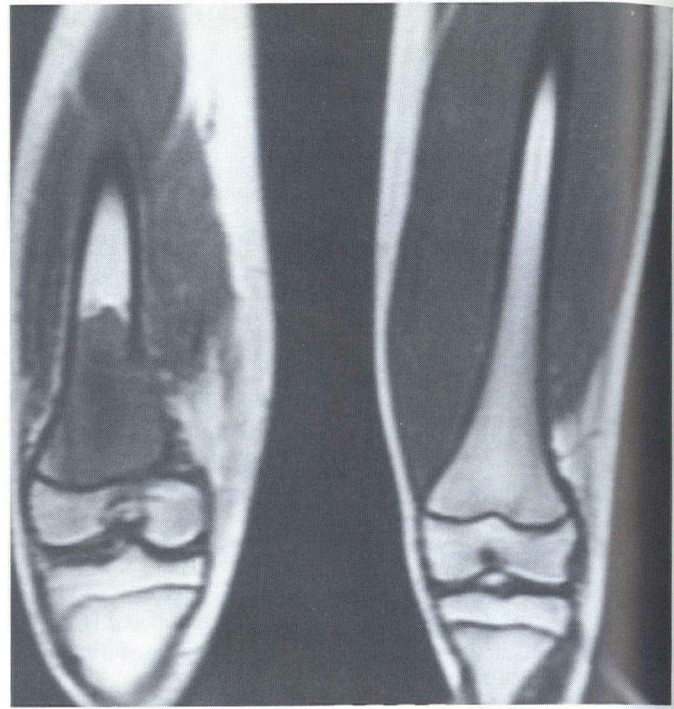


*Fig 11—Teenager with lateral joint line pain not typical for meniscal injury. Coronal T2-weighted image (SE2500/75 msec). T2 weighting facilitates visualization of a fluid-filled structure. Two fluid-filled structures are seen over the head of the fibula and just lateral to the tibial plateau compatible with abnormally distended lateral fibular bursae (arrow).*

metastases; radionuclide scintigraphy and plain film radiography remain the imaging procedures of choice. The exception may be in the detection of disseminated lesions of multiple myeloma, in which the radionuclide bone scan is often negative despite widespread disease. An early study suggests that MRI may be a sensitive modality in detecting these lesions (21).

### Marrow Infiltrative Disorders

The characteristic high-intensity signal of fat makes MRI an excellent tool for evaluation of bone marrow. In the adult (after age 25), most of the appendicular bone marrow is composed of fat (22); therefore, normal bone marrow will appear bright on both T1- and T2-weighted images (Fig 2). Any marrow infiltrating disorder which replaces the fat in marrow (eg, by neoplastic cells or fibrosis) will cause decreased signal intensity on T1-weighted images (22,23). Signal intensity on T2-weighted images has been found to be variable (21). The same principle applies to MRI of bone marrow infiltrative disorders in children; however, because of the lower content of fatty marrow (increased content of hematopoietic marrow), the normal MRI ap-



*Fig 12—Osteogenic sarcoma (same patient as in Fig 1). Coronal T1-weighted image demonstrates a geographic area of fairly homogenous diminished signal intensity with destroyed medial cortex. Lesion extends to growth plate which is easily visible. MR findings are compatible with osteogenic sarcoma, although conventional radiographs should be relied upon to characterize the lesion.*

pearance of a child's marrow will be of homogeneously lesser signal intensity relative to adults. This can make distinction of infiltrated marrow versus normal marrow difficult in children (22).

The clinical utility of MRI in diagnosing and assessing the extent of marrow infiltrative disorders such as leukemia, lymphoma, and myelofibrosis is uncertain. Presently, MRI is nonspecific in the diagnosis of these entities. However, MRI may be useful in identifying sites of abnormal marrow for biopsy (21). MRI might also be of future value in following response to chemotherapy or bone marrow transplantation.

### Osteomyelitis of the Extremities

As in other infiltrative disorders, MRI is sensitive in demonstrating changes secondary to the infiltrative exudate/edema seen in acute osteomyelitis (24). Signal intensity is generally diminished on T1-weighted images (Fig 15) and generally (but not invariably) increased on T2-weighted images (25,26). The findings are nonspecific and must be distinguished from neoplasm, fibrosis, or other infiltrating processes. Therefore, correlation with clinical data and other imaging modalities (especially radionuclide studies) is imperative. MRI appears to detect changes in the bone at approximately the same time as abnor-

*Fig 13—evident. determin tumor ma*

malities a plain film diagnosis is lished. In distinguish

With it fashion, arthritis, radiograph previously de potentiall facial in th as conger iopathic d

MRI is conventi tomograp orders of

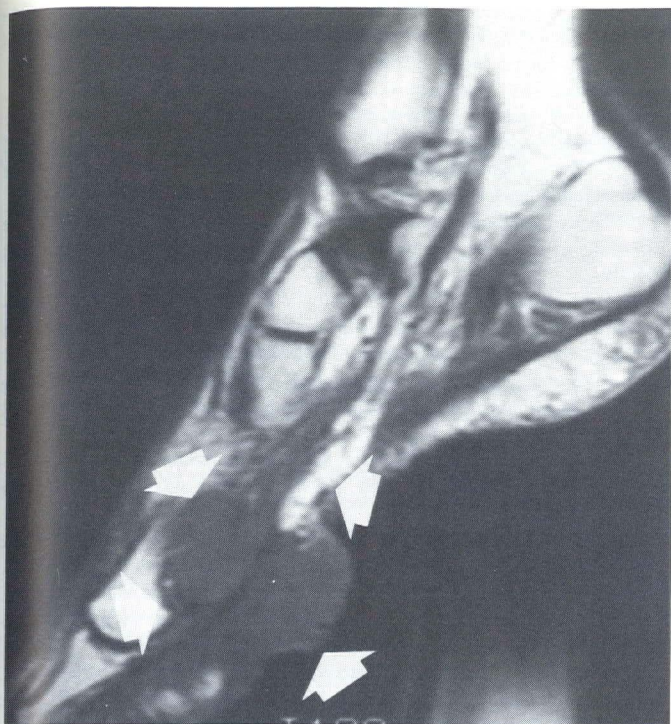


Fig 13—Synovial sarcoma of the foot. Bulky, fungating lesion evident. The predominant value of MRI in this instance was determining a level for amputation. Note excellent display of tumor margins (arrows).

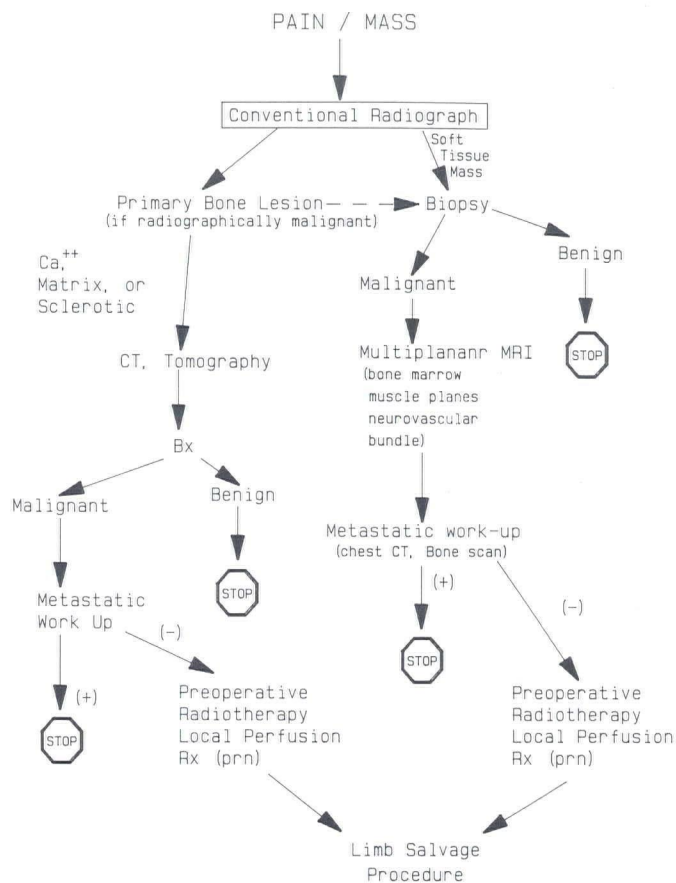


Fig 14—Algorithm. (The stop sign indicates that no further imaging is required.)

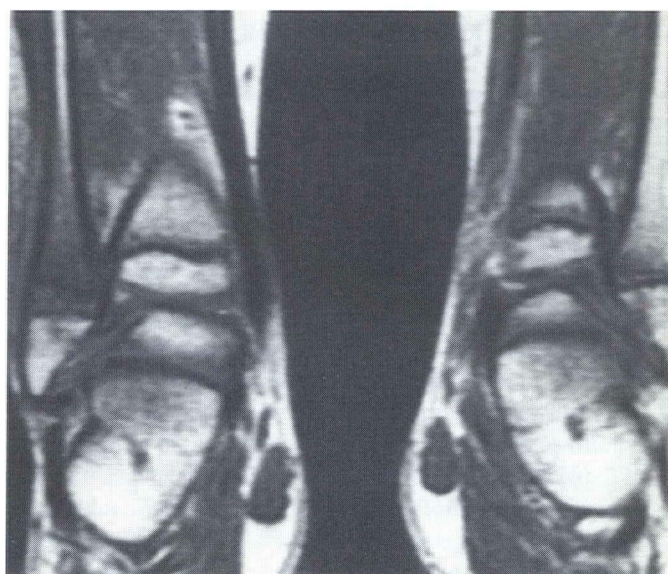

Fig 15—Patient with abnormal bone scan and ankle pain. There is diminished signal intensity involving subcutaneous fat of the right ankle. Usual high signal intensity of distal fibula is lost due to inflammatory changes from osteomyelitis. Changes in bone and underlying soft tissues are indicative of an inflammatory process.

malities are seen in radionuclide scintigraphy but earlier than plain film radiography (24,25). The exact role of MRI in the diagnosis and management of acute osteomyelitis is not established. In cases of chronic osteomyelitis, MRI may be helpful in distinguishing active versus healed cases (24).

### Miscellaneous

With its unique ability to visualize cartilage in a noninvasive fashion, MRI seems well suited to evaluate early changes of arthritis, perhaps before they become visible on plain film radiography. Likewise, diseases of synoviae and bursae, previously demonstrated only on arthrography/arthroscopy, should potentially be detected by MRI. MRI could prove to be beneficial in the early, noninvasive detection of other disorders such as congenital hip dislocation, compartment syndromes, and idiopathic disorders (eg, osteochondritis dissecans).

### Conclusion

MRI is rapidly supplanting or becoming a valuable adjunct to conventional imaging modalities, particularly computed tomography, in the evaluation and management of several disorders of the musculoskeletal system. As further clinical experi-

ence is gained with this modality, indications for its use and its place in the orderly workup of musculoskeletal disorders will become apparent.

## References

1. Haggart AM, Kressel HY. Magnetic resonance imaging of the genitourinary tract. *Urol Clin North Am* 1985;12:725-36.
2. Hungerford DS, Lennox DW. The importance of increased intraosseous pressure in the development of osteonecrosis of the femoral head: Implications for treatment. *Orthop Clin North Am* 1985;16:635-54.
3. Steinberg ME, Brighton CT, Hayken GD, Tooze SE, Steinberg DR. Early results in the treatment of avascular necrosis of the femoral head with electrical stimulation. *Orthop Clin North Am* 1984;15:163-75.
4. Mitchell MD, Kundel NL, Steinberg ME, Kressel HY, Alavi A, Axel L. Avascular necrosis of the hip: Comparison of MR, CT, and scintigraphy. *AJR* 1986;147:67-71.
5. Sweet DE, Madewell JE. Pathogenesis of osteonecrosis. In: Resnick D, Niwayama G, eds. *Diagnosis of bone & joint disorders*. Philadelphia: Sanders, 1981:2780-831.
6. Totty WG, Murphy WA, Ganz WI, Kumar B, Daum WJ, Siegel BA. Magnetic resonance imaging of the normal and ischemic femoral head. *AJR* 1984;143:1273-80.
7. Gillespy T III, Genant HK, Helms CA. Magnetic resonance imaging of osteonecrosis. *Radiol Clin North Am* 1986;24:193-208.
8. Reinus WR, Conway WF, Totty WG, et al. Carpal avascular necrosis: MR imaging. *Radiology* 1986;160:689-93.
9. Hartzman S, Reicher MA, Bassett LW, Duckwiler GR, Mandelbaum B, Gold KH. MR imaging of the knee. Part II. Chronic disorders. *Radiology* 1987;162:553-7.
10. Sierra A, Potchen EJ, Moore J, Smith HG. High-field magnetic-resonance imaging of aseptic necrosis of the talus: A case report. *J Bone Joint Surg [Am]* 1986;68A:927-8.
11. Reicher MA, Bassett LW, Gold RH. High-resolution magnetic-resonance imaging of the knee-joint—pathologic correlations. *AJR* 1985;145:903-9.
12. Lotysch M, Mink J, Crues JV. Detection of meniscal injuries using magnetic resonance imaging. In: *Book of abstracts. Society of Magnetic Resonance in Medicine*, August 19-22, 1986;4:1197.
13. Reicher MA, Hartzman S, Bassett LW, Mandelbaum B, Duckwiler G, Gold RH. MR imaging of the knee. Part I. Traumatic disorders. *Radiology* 1987;162:547-51.
14. Li DKB, Adams ME, McConkey JP. Magnetic resonance imaging of the ligaments and menisci of the knee. *Radiol Clin North Am* 1986;24:209-27.
15. Turner DA, Prodromos CC, Petasnick J, Clark JW. Acute imaging of the ligaments of the knee: Magnetic resonance evaluation. *Radiology* 1985;154:717-22.
16. Hudson TM, Hamlin DJ, Enneking WF, Pettersson H. Magnetic resonance imaging of bone and soft tissue tumors: Early experience in 31 patients compared with computed tomography. *Skeletal Radiol* 1985;13:134-46.
17. Aisen AM, Martel W, Braunstein EM, McMillin KI, Phillips WA, Kling TF. MRI and CT evaluation of primary bone and soft-tissue tumors. *AJR* 1986;146:749-56.
18. Pettersson H, Hamlin DJ, Scott K. Magnetic resonance imaging of primary musculoskeletal tumors. *CRC Critical Reviews in Diagnostic Imaging* 1986;26:241-63.
19. Zimmer WD, Berquist TH, McLeod RA, et al. Bone tumors: Magnetic resonance imaging versus computed tomography. *Radiology* 1985;155:709-18.
20. Sundaram M, McGuire MH, Herbold DR, Wolverson MK, Heiberg E. Magnetic resonance imaging in planning limb-salvage surgery for primary malignant tumors of bone. *J Bone Joint Surg [Am]* 1986;68A:809-19.
21. Daffner RH, Lupetin AR, Dash N, Deeb ZL, Sefczek RJ, Schapiro RL. MRI in the detection of malignant infiltration of bone marrow. *AJR* 1986;146:353-8.
22. Porter BA, Shields AF, Olson DO. Magnetic resonance imaging of bone marrow disorders. *Radiol Clin North Am* 1986;24:269-89.
23. Cohen MD, Klatter EC, Baehner R. Magnetic resonance imaging of bone marrow disease in children. *Radiology* 1984;151:715-8.
24. Modic M, Pflanze W, Feiglin DHI, Belhobels G. Magnetic resonance imaging of musculoskeletal infections. *Radiol Clin North Am* 1986;24:247-58.
25. Fletcher BD, Scoles PV, Nelson AH. Osteomyelitis in children: Detection by magnetic resonance. *Radiology* 1984;150:57-60.
26. Bloem HL, Falkes THM, Doornbos J. Osteomyelitis in children: Detection by magnetic resonance (letter). *Radiology* 1984;153:263-4.

Extraneoplasmic system Registry, the 100,000 peripheral plasma cell multiple myelomas (EMPs) by W passages, 6 spleen, 3% in the testis respond to hoarseness, include lymph pain, or gas EMP is c or two extra bone marrow (1,15,16). In EMPs developed beyond lymph recurred local contrast, the progressed solitary plasmacytoma of multiple clinical entities. Numerous therapy, or appropriate management rates of 60% study review